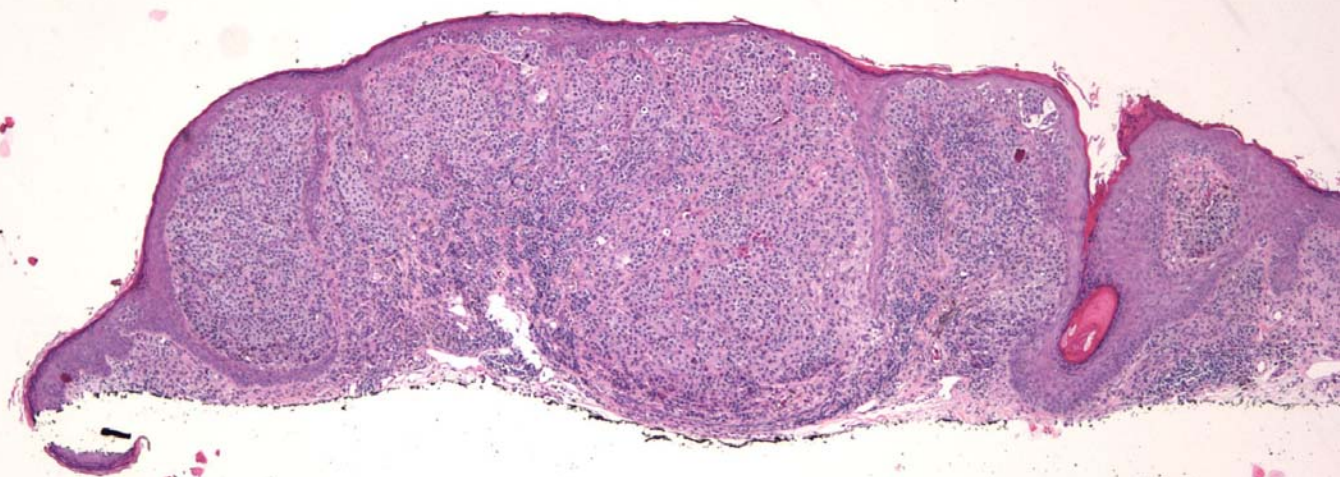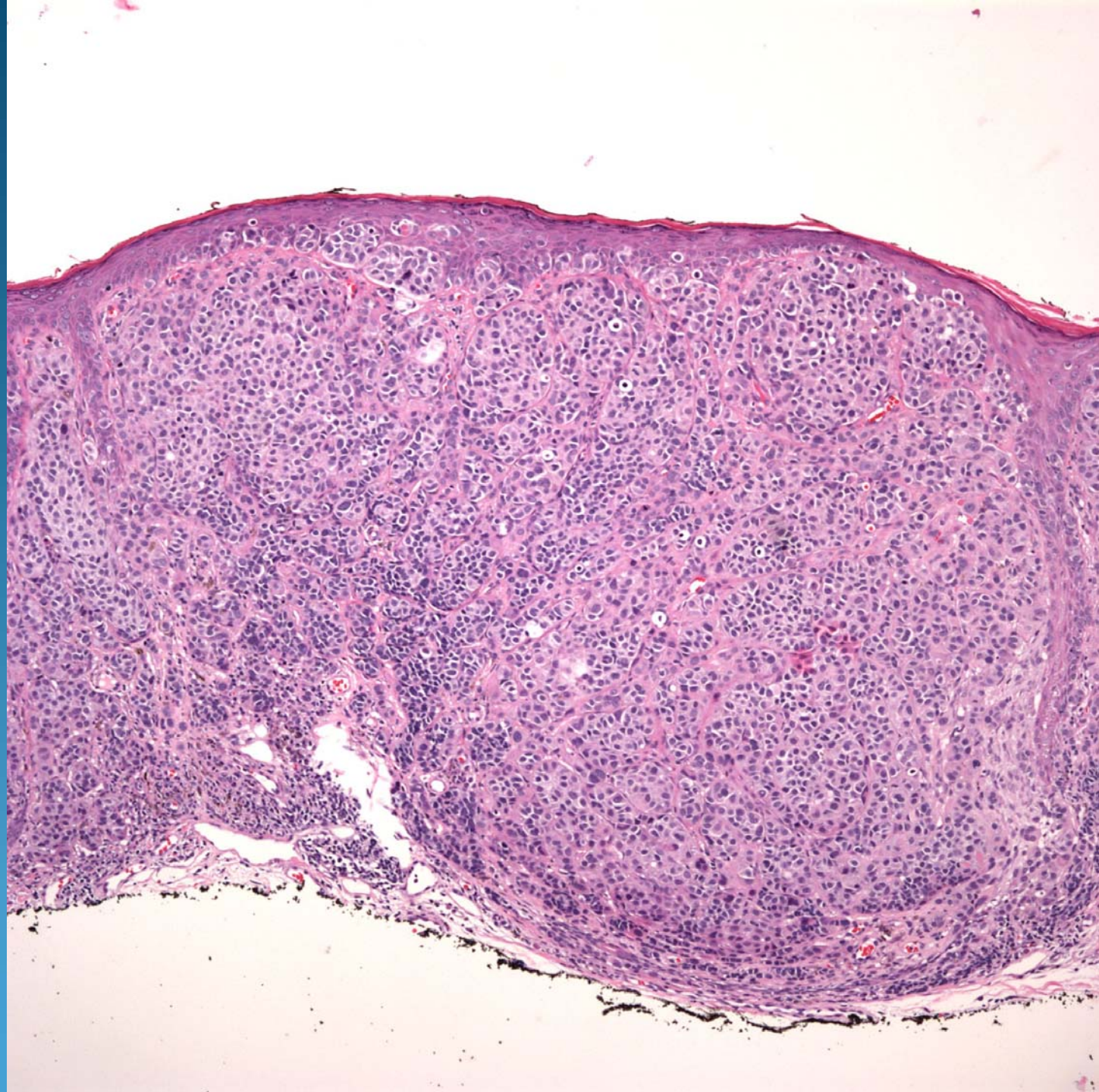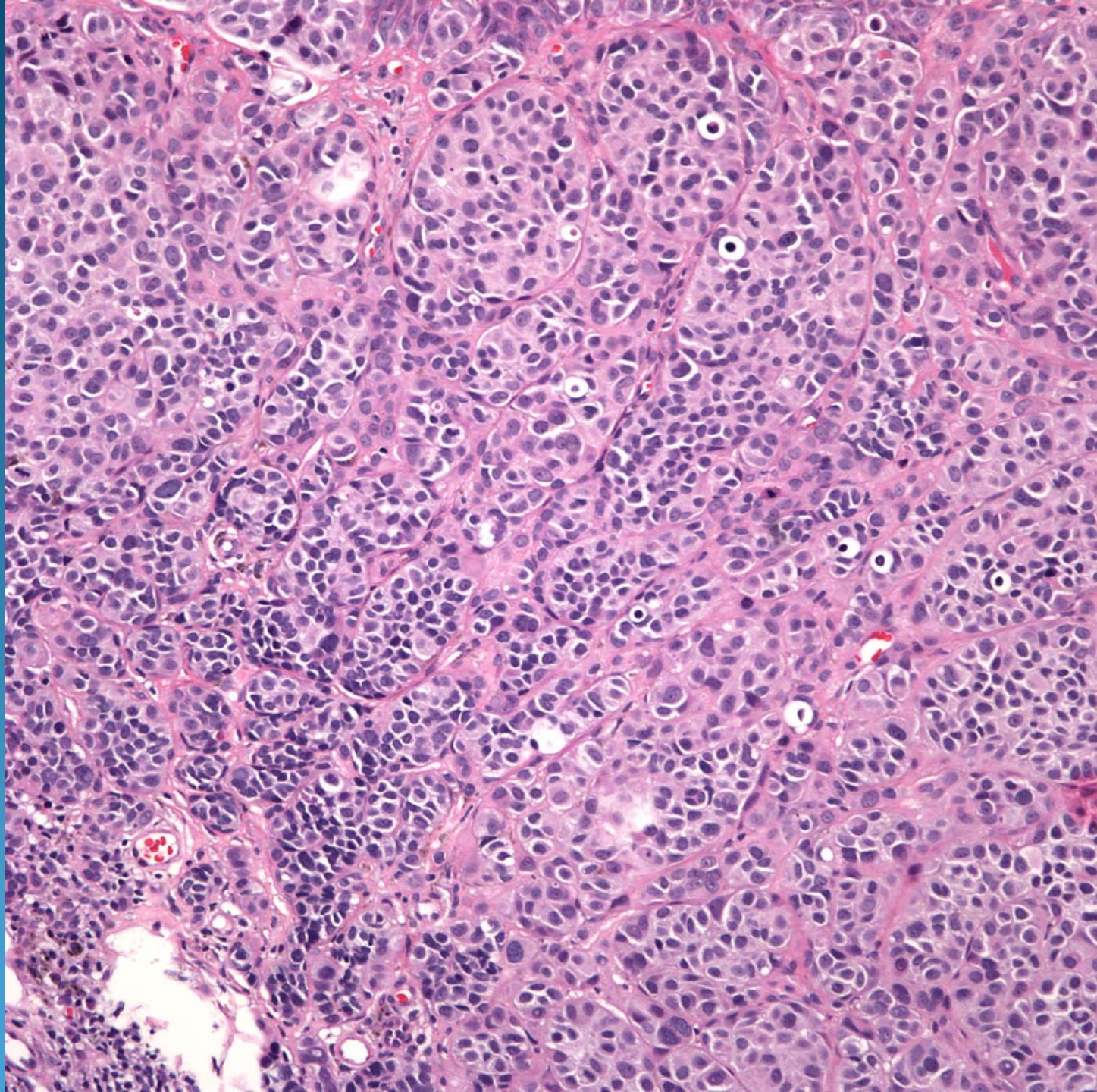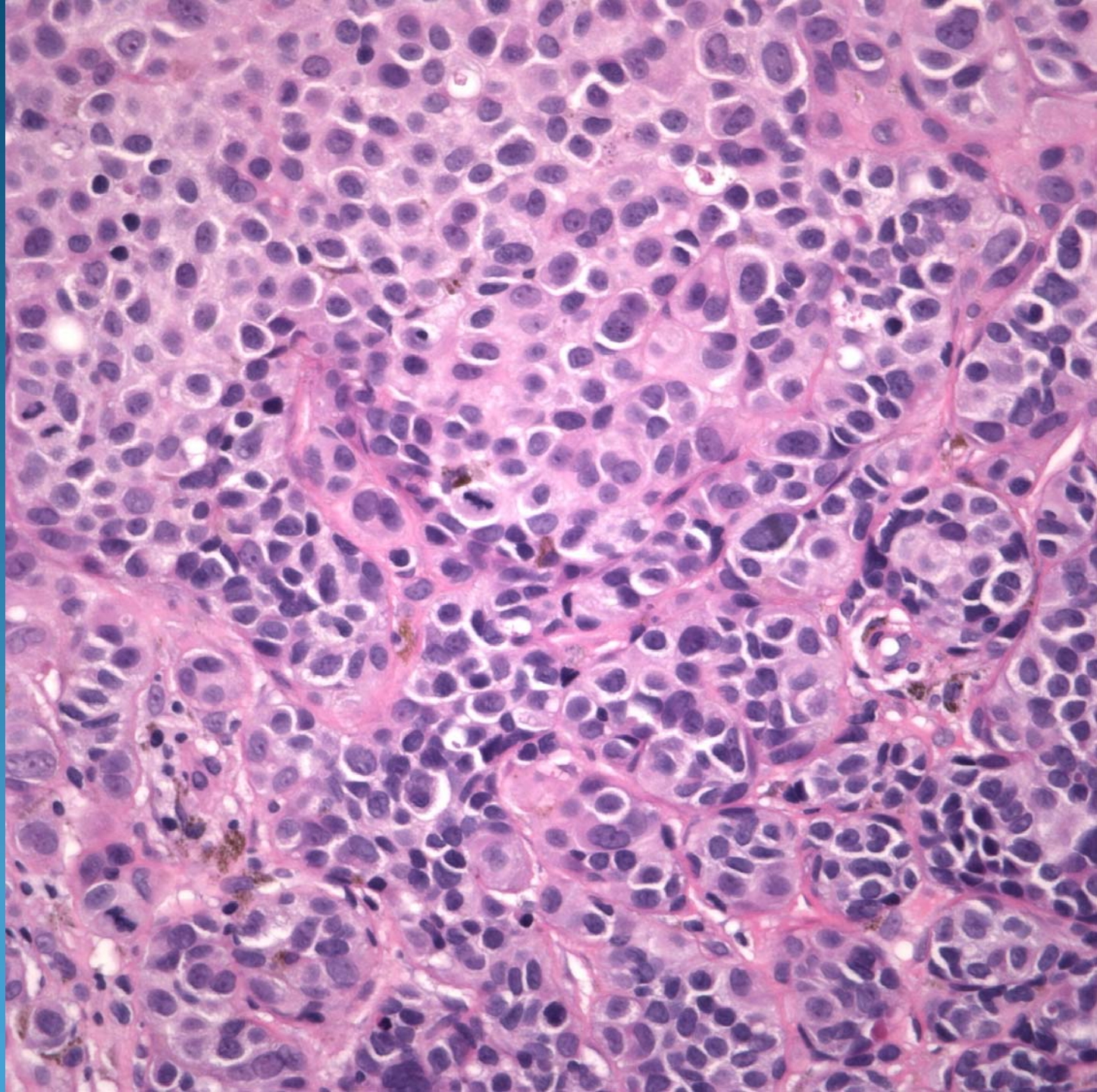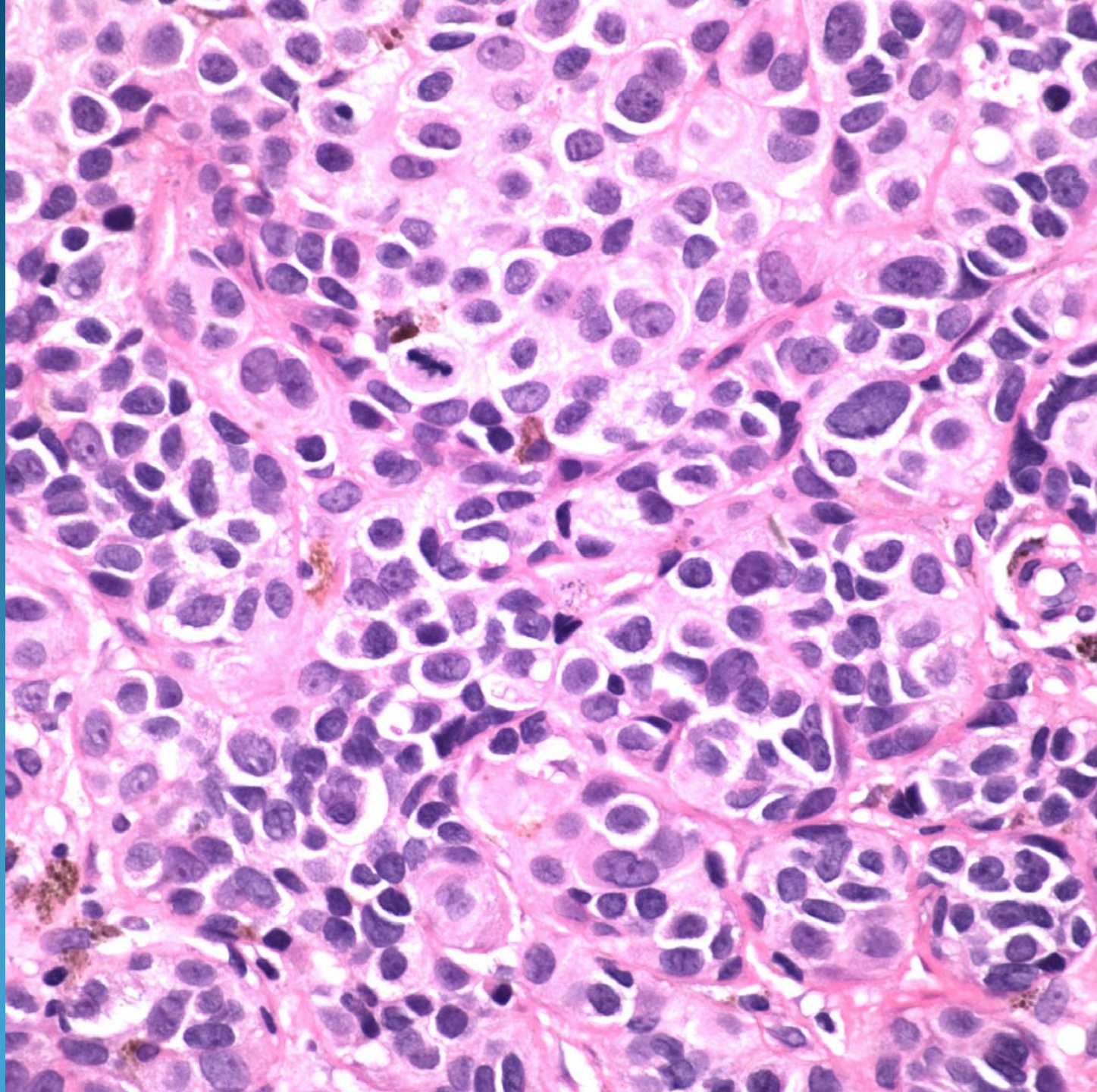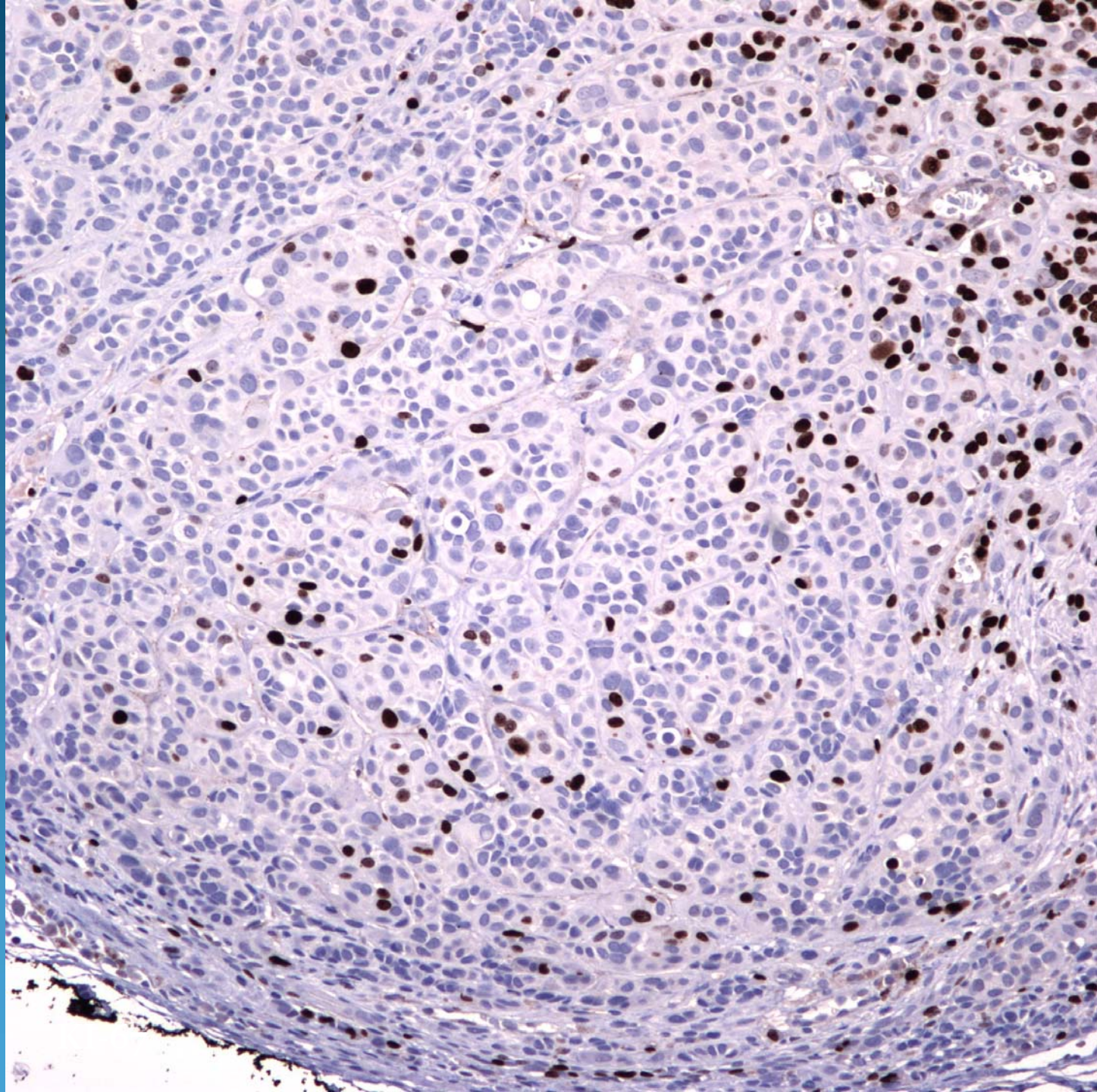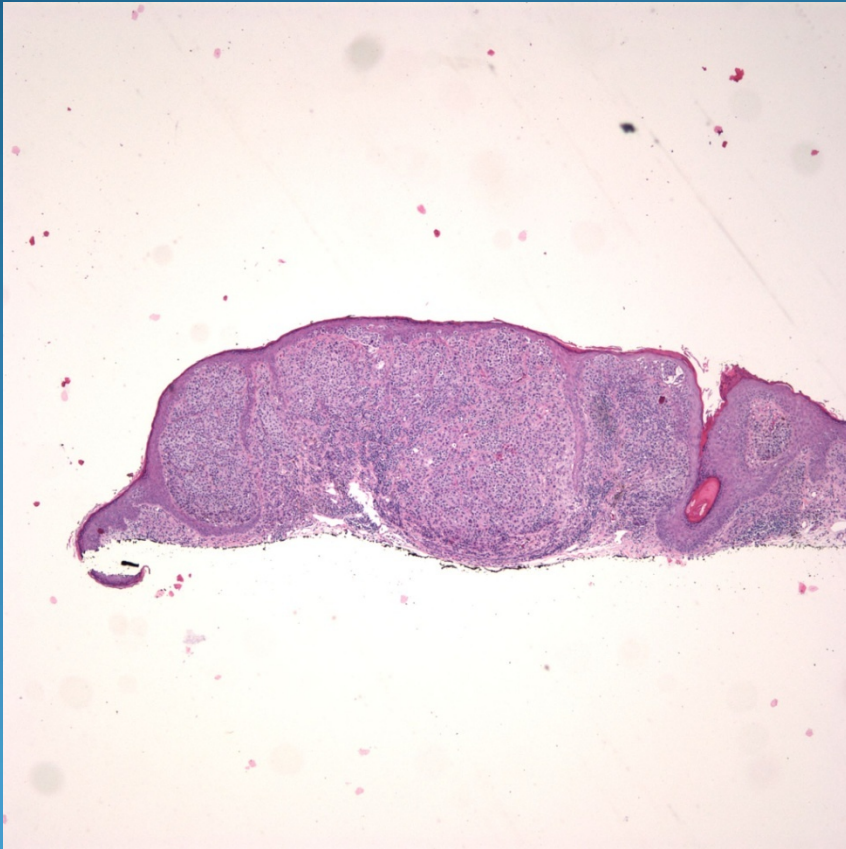


Malignant Melanoma, Nevoid Type

Pearls



- Low power architecture of a benign melanocytic nevus
- Cytologically atypical melanocytes present at base of lesion
- Mitotic figures at base
- Ki-67 may be helpful to label melanocytes at the base